

Reply to the Letter to the Editor: "Evaluation of Reporting Deficiencies, Methodological Gaps, and Hemodynamic Paradoxes in the ScienCrown Transcatheter Valve: A Comprehensive Critical Analysis"

LETTER TO THE EDITOR REPLY

To the Editor,

Thank you for forwarding¹ the concerns raised by the experts regarding our case report.² We take these comments seriously and have meticulously verified the original clinical data, imaging materials, and procedural records item by item. Below is a detailed explanation and supplementary information addressing each question, with the goal of upholding academic transparency and data accuracy.

EXPLANATION OF THE "HEMODYNAMIC PARADOX" AND MEASUREMENT BIAS

First, measurements of transvalvular pressure gradients and valve orifice flow velocities are influenced by multiple objective factors, including differences between transesophageal echocardiography and transthoracic echocardiography equipment, the ultrasound technician's clinical experience, selection of imaging planes, and fluctuations in the patient's physiological status. These factors contribute to reasonable variability in measurements, which aligns with the routine clinical characteristics of ultrasonic examinations.

Notably, owing to an editorial oversight on our part, the ultrasonic image of the aortic valve presented in Figure 2 of the original manuscript² contained an erroneous pasting error (Figure 2D), and we sincerely apologize for this mistake. We hereby submit the corrected immediate postoperative ultrasonic measurement images and data (Figure 1). As shown in Figure 1D, the immediate postoperative mean transaortic pressure gradient was 11 mm Hg (rather than the 6 mm Hg reported in the original manuscript).

SUPPLEMENTARY INFORMATION ON MISSING KEY PROCEDURE DETAILS

Regarding the missing perioperative parameters, we appreciate the reviewers' valuable comments. We acknowledge this as a critical oversight and have now supplemented it with the following information: (1) total operative time: 200 minutes (from anesthesia induction to final skin suture); (2) contrast agent volume: 180 mL (Iodixanol 320 mgI/mL); (3) postoperative acute kidney injury (AKI) assessment: According to the KDIGO criteria, the peak creatinine level was 76 $\mu\text{mol/L}$ (consistent with the preoperative level), which did not meet the criteria for AKI; and (4) electrocardiogram (ECG) changes: Compared with the preoperative ECG, the postoperative ECG showed aggravated conduction block (PR interval prolonged from 228 milliseconds to 238 milliseconds), which returned to 220 milliseconds at discharge.

Complete original records of the supplementary data are retained. Please do not hesitate to contact us if the editorial team or expert panel requires these materials for further review and verification.

Jian-Dong Ding¹ 

Yi-Lin Chen¹ 

Rong-Feng Xu¹ 

Xiao-Li Zhang¹ 

Qi-Tong Lu² 

Gen-Shan Ma¹ 

¹Department of Cardiology, Zhongda Hospital, Southeast University, Nanjing, China

²Department of Cardio-Thoracic Surgery, Zhongda Hospital, Southeast University, Nanjing, China

Corresponding author:

Jian-Dong Ding
✉ dingjiandong@163.com

Available Online Date: April 19, 2026

Cite this article as: Ding J, Chen Y, Xu R, Zhang X, Lu Q, Ma G. Reply to the letter to the editor: "Evaluation of reporting deficiencies, methodological gaps, and hemodynamic paradoxes in the ScienCrown transcatheter valve: A comprehensive critical analysis". *Anatol J Cardiol*. 2026;30(6):407-409.

DOI: 10.14744/AnatolJCardiol.2026.6225



Copyright@Author(s) - Available online at anatoljcardiol.com.
Content of this journal is licensed under a Creative Commons Attribution-NonCommercial 4.0 International License.

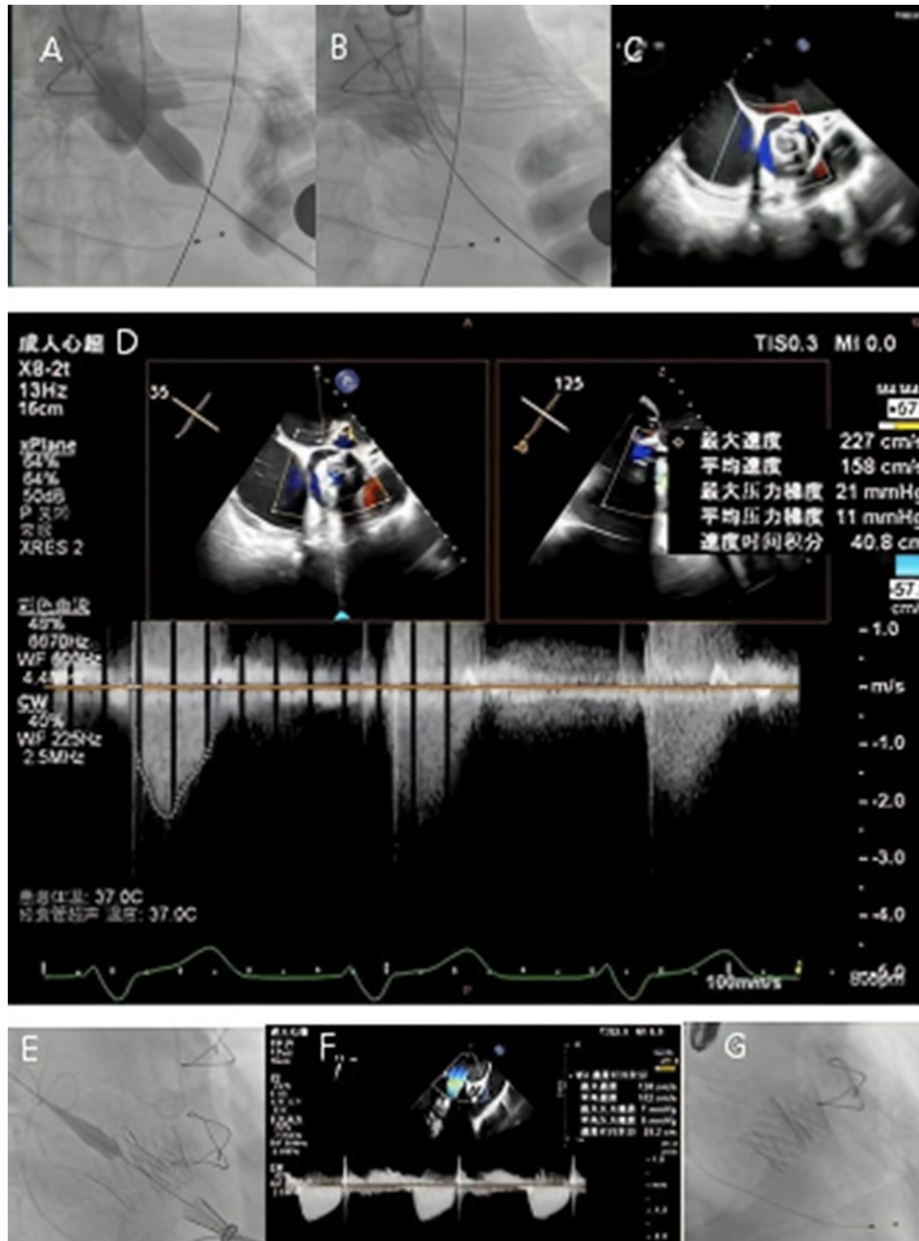


Figure 1. Transapical aortic and mitral ViV procedure using ScienCrown. A: An 18-mm balloon aortic valvuloplasty pre-dilation. B: Successful 21 mm ScienCrown deployment demonstrating absence of paravalvular leak. C: Post-implantation transesophageal echocardiography (TEE) confirming no paravalvular leakage. D: Post-procedural TEE documenting a mean aortic gradient of 11 mm Hg. E: Optimal 25 mm ScienCrown placement in mitral position. F: Post-deployment TEE assessment showing a mean mitral gradient of 5 mm Hg. G: Postoperative imaging demonstrating appropriate spatial orientation and stent expansion for both implanted valves.

EXPLANATION OF THE SAFETY OF USING A 27-FRENCH SHEATH VIA THE TRANSAPICAL APPROACH

First, the patient experienced no transapical approach-related complications (e.g., pseudoaneurysm, bleeding, or myocardial wall motion abnormalities) during or after the procedure. Second, as an important access route for transcatheter aortic valve implantation, its safety has been clinically validated.^{3,4} The apical double purse-string suture technique employed in this procedure effectively prevents the majority of severe bleeding events associated with the

transapical approach. Third, the sheaths used for establishing peripheral vascular access in the transapical procedure are small in diameter; proper selection of the puncture site and standardized puncture technique can effectively avoid severe peripheral vascular complications.⁵

The transapical approach offers several advantages: a short distance to the mitral valve, excellent coaxial alignment, high procedural controllability, simplified surgical manipulation, and ease of technical popularization.⁶ Its main limitation is the requirement for a small intercostal incision and

apical puncture, which are associated with minimal trauma. In contrast, the transseptal approach provides the benefit of less invasive access without the need for an intercostal incision but is constrained by a longer access path, stringent requirements for the operator's atrial septal puncture experience, suboptimal mitral valve coaxiality, and high technical complexity. For the patient in this case, the transapical approach was a clinically appropriate choice for interventional treatment.

Finally, it is important to clarify that in the study data by Professor Chen et al⁷ cited in the reviewers' comments, 9.38% (12/128) of vascular complications were attributed to the transfemoral approach cases (n=122), rather than the transapical approach cases (n=6). This finding further confirms the safety of delivering the ScienCrown valve system via the transapical approach in this case.

In conclusion, we endorse the principle of "full transparency" emphasized in the reviewers' comments and are prepared to provide original data for review by the editorial team and expert panel.

Once again, we express our gratitude to the editorial team and contributing experts for their rigorous peer review.

Declaration of Interests: The authors have no conflicts of interest to declare.

Funding: The authors declare that this study received no financial support.

REFERENCES

1. Cömert AD, Şentürk N. Evaluation of Reporting Deficiencies, Methodological Gaps, and Hemodynamic Paradoxes in the ScienCrown Transcatheter Valve: A Comprehensive Critical Analysis. *Anatol J Cardiol.* 2026; 30(6):405-406.
2. Ding JD, Chen YL, Xu RF, Zhang XL, Lu QT, Ma GS. ScienCrown valve: a novel transcatheter heart valve for concurrent aortic and mitral valve-in-valve implantation in bioprosthetic degeneration. *Anatol J Cardiol.* 2025;30(1):55-58. [\[CrossRef\]](#)
3. Aguirre J, Waskowski R, Poddar K, et al. Transcatheter aortic valve replacement: experience with the transapical approach, alternate access sites, and concomitant cardiac repairs. *J Thorac Cardiovasc Surg.* 2014;148(4):1417-1422. [\[CrossRef\]](#)
4. Tabata M. Transapical approach in transcatheter cardiovascular interventions. *Gen Thorac Cardiovasc Surg.* 2018;66(4):185-191. [\[CrossRef\]](#)
5. Mach M, Okutucu S, Kerbel T, et al. Vascular complications in TAVR: incidence, clinical impact, and management. *J Clin Med.* 2021;10(21):5046. [\[CrossRef\]](#)
6. You T, Wang W, Yi K, et al. Transcatheter mitral valve replacement for degenerated mitral valve bioprostheses, failure of mitral valvuloplasty and native valve with severe mitral annulus calcification: a systematic review and meta-analysis. *J Cardiothorac Surg.* 2021;16(1):293. [\[CrossRef\]](#)
7. Chen Y, Liu Q, Zhang H, et al. Transcatheter aortic valve replacement with a fully-recyclable self-expanding short-frame scienCrown valve for severe aortic stenosis. *Int J Surg.* 2025;112(2):3338-3347. [\[CrossRef\]](#)